

## NOVOCAINE BLOCKADE IN THE TREATMENT OF LEPROSY

BY A. A. VISHNEVSKY, JR., M.D.

*From the "Krutje Ruchi" Leper Settlement  
Weimarn, Leningrad, U.S.S.R.<sup>1</sup>*

My work on the treatment of leprosy by injections of novocaine solution, proposed by Professor Speransky and carried out in collaboration with M. Sheheperin, was published in Moscow in 1935. The method used, which acts on the nervous system of the patient, was worked out for the treatment of inflammatory and trophic processes by A. V. Vishnevsky, who called it "novocaine blockade of nerves." Since then communications by Kuznetsov, Peshkovsky, Podvisotzkaia and others have appeared which confirm our results with this treatment in leprosy. I have continued the work in the surgical clinic, applying the method to various diseases of other etiologies, and have acquired a clearer idea of its mechanism of action. This permits me now to evaluate the results in leprosy from a somewhat different point of view than that held three years ago.

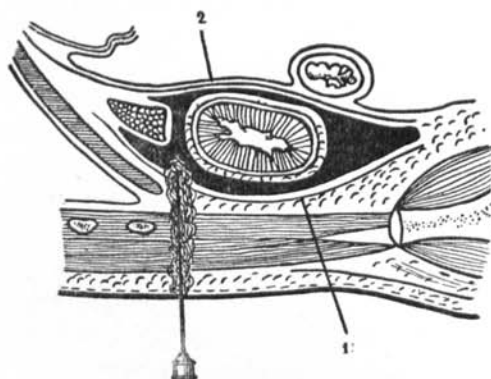
In 1901 Spies and certain others drew attention to the beneficial influence of anesthetics on the acute inflammatory process. These observations correspond with those of A. V. Vishnevsky on local infiltration anesthesia in the operative treatment of inflammatory diseases. The positive results observed he explained by an action of the novocaine solution on the trophic function of the nervous system, and he obtained therapeutic effects on using this method of anesthetization in substitution for certain surgical operations on the nervous system.

Two methods were proposed: (a) blockade of the sympathetic system of the lumbar region and the adjoining part of cerebrospinal nerves, and (b) circular blockade of the extremity, completely interrupting its innervation. The first scheme is analogous with the operations on the sympathetic system: excision of lumbar sympathetic ganglions (Diez), dissection of the rami communicantes (Royle), removal of the suprarenal gland with injury of the sympathetic system (Oppel). The second scheme is analogous with interference

<sup>1</sup>Director, M. G. Kartashov; scientific consultant, A. A. Stein.

with the peripheral nervous system: neurotomy (Chipault, Volkmann, Molotkov and others), exclusion of the sympathetic innervation along arteries (Leriche), injection of novocaine in an opened vessel sheath (Ford).

An investigation of the anatomical features of lumbar blockade was made by me with Rupassov. An unembalmed corpse was placed on its side as for a kidney operation and a needle was introduced perpendicularly to the skin in the hollow between the twelfth rib and *m. sacrospinalis*; it was pushed inward until muscular resistance ceased. A warm, colored gelatine solution (100-150 cc.) was introduced under pressure, and the corpse was fixed and sectioned. The injection mass was found to have spread between the anterior and posterior laminae of the renal fascia. When more solution was used, it spread over the anterior surface of the kidney behind the anterior layer of the renal fascia, and thus surrounded the kidney (Text-fig. 1). As a rule it also extended along the vessels, coming into contact with the renal and suprarenal plexuses, the suprarenal gland and, through diffusion, with other nerve structures of the abdominal organs, chiefly the sympathetic chain (Text-fig. 2).



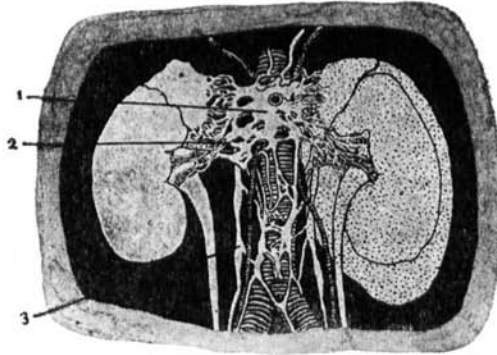
TEXT-FIG. 1. Showing the distribution of the injection mass (black) between the laminae of the renal fascia when injected by the technique described. 1. Lamina renalis posterior. 2. Lamina renalis anterior.

The technique of the lumbar novocaine blockade is as follows:

The patient is placed on his side as for a kidney operation; a bolster is indispensable. After superficial anesthetization of the area mentioned above, a long needle (8-10 cm.) attached to a large syringe (12-20 cc.) is introduced, perpendicularly to the surface. Continuous injection of the solution precedes the forward movement of the needle. The syringe is periodically removed from the needle for a control on blood. Penetration of the interfascial space can be recognized by cessation of resistance to the needle and by the fact that the novocaine solution begins to flow easily. The solution used is 0.25 percent novocaine with 2 drops of adrenalin per 100 cc. As much as 150 to 200 cc. can be introduced readily in an adult. We have also applied this method to children and have observed no bad results directly connected with the injection technique.

Circular blockade of the nerves of the extremity is done as follows:

Subdermal wheals are established around the extremity with a small syringe. From there the subcutaneous tissue is infiltrated with a large syringe. Then, bearing in mind the vessel topography, three punctures introduce the solution under the aponeuroses to the bone. This operation requires 150-200 cc. of the novocaine solution. The extremity is bandaged for a day.



TEXT-FIG. 2. Showing distribution of the injection mass (indicated by dots) in the renal fascia and its relation to the nervous system. 1. Plexus solaris. 2. Plexus renalis. 3. Truncus sympathicus lumbalis.

Applying novocaine blockade as a therapeutic measure in different diseases, it was soon evident that it had an influence upon the course of all the acute inflammatory processes (carbuncle, phlegmon, erysipelas, epididymitis); it either stopped or limited them, depending upon their stage or character. In the stage of serous exudate and initial cellular infiltration the inflammatory process resolved. When there was pronounced cellular infiltration, a liquidation of the process occurred, with suppuration. Some therapeutic effect was also seen in chronic inflammatory conditions, including gastric ulcer and incurable ulcer of the extremity. Processes having a slow course, with prevailing necrobiotic phenomena, exacerbated and the acute inflammatory component took the leading part in the pathologic process; it soon resolved and was followed by regeneration.

In our work on leprosy we treated about one hundred patients during two years. In all cases the novocaine blockade was more or less beneficial. We can divide our observations into three groups.

#### GROUP I

The first group comprises about fifty patients for whom the novocaine blockade changed the course of local pathologic foci—

patches, nodules, edema, purulent ulcers. As examples, the records of two very advanced cases are given in summary. Chaulmoogra treatment of these patients had not given any results.

CASE 1. N., female, aged 21, mixed leprosy. Red nodules on the forearms and feet were first noticed at the age of 7; disease diagnosed in 1923, since when the patient has been in the settlement. Patient of normal build, well nourished; principal skin changes on face and extremities. Vision and hearing normal, voice husky, respiration obstructed in spite of tracheotomy. Face typically leonine, infiltrated and studded with nodules, eyebrows absent, nose deformed. Brown patches on body. Skin of extremities much infiltrated, with many thick nodules. Hands and feet edematous, pronouncedly cyanotic. Skin sensitivity lacking on face and extremities, present on trunk, diminished elsewhere. *M. leprae* abundant in the nasal secretion and the ulcers.

Ulcers of legs (Plate 34, fig. 1): One on anterior surface of left leg, 6x7 cm., borders calloused, floor necrotic in places, granulations flabby and cyanotic, very painful; secretion serous, putrescent, not abundant; it appeared two years ago after a contusion. Three on the right leg; two, each 5x5 cm., with irregular thick borders, floor in places necrotic, appeared suddenly about three months ago after an insignificant cold; the third, small and round, granulations cyanotic with slight hemorrhage, appeared about a month ago; these ulcers are almost painless; and the process is more acute than on the left leg.

On February 2, 1934, blockade was administered in the left lumbar region, 150 cc. Three hours later the ulcers of the right leg became painful, while the pain in the left leg abated. Evening temperature 38.5°C., normal next day. For two days the serous secretion was more abundant, the appearance of the ulcers more lively, but by February 8 there was marked relapse.

A second blockade was administered on February 10th, 80 cc., right lumbar. Evening temperature 38.2°C. but normal next day; the ulcers were then fresher, secretion odorless, the upper ones on the right leg diminished. Improvement continued on the left side, but a blister appeared over the ulcers on the right leg; contents bloody-suppurative and surface, after opening, of necrotic character. The lateral ulcer on this leg had enlarged. This exacerbation continued until the appearance on March 3 was as shown in Plate 34, fig. 2. At the same time the skin of the extremities, until now very hard and stiff, and of the face had become more elastic and soft and less cyanotic.

On March 6 a circular blockade of the right thigh was performed. Thereafter improvement was fairly steady except that on April 3 a new ulcer appeared on the left leg; that healed within two weeks. In another month and a half all ulcers were healed (Plate 34, fig. 3).

The general state of the patient was good, the infiltration of the skin and the edema decreased, the skin more elastic and in some places of nearly normal color. In many places there was restoration of sensitivity. Two months later, after an attack of grippe, two ulcers opened again on the legs and nodules reappeared in places where they had been before the treatment. The ulcers were not so large as the previous ones, and they soon healed with no treatment but bandaging.

CASE 2. P., male, aged 49, mixed leprosy. First symptom was diminution of vision; nodules soon appeared on the face and chin. Entered the settle-

ment in 1922 with lesions of the face and extremities. Patient very exhausted and quite blind. Ulcers of tongue and hard palate and in the nose. Face covered with nodules and scars, thickly infiltrated and of earthy color. Large brown patches on abdomen, trunk, buttocks and thighs. On forearms, hands and feet numerous subcutaneous nodules, thick, and painless; skin of forearms dry, cyanotic, liable to injury; small ulcers on all fingers, which are in the state of "main en griffe" (Plate 34, figs. 4 and 5). On left ankle an oval ulcer 4 x 2.5 cm., painless, borders sloping, regular, floor flat with a dirty deposit (Plate 34, fig. 8); duration about 4 years. *M. leprae* obtained from the mouth and nose ulcers, not from that of the foot. All kinds of skin sensitivity absent on face and extremities; present in some places on the trunk, absent in others.

On February 19, 1934, left lumbar blockade, 80 cc. Immediate headache, and in the evening pain in the foot ulcer; temperature 38.2°C. On the following day increased secretion from the ulcer, edema of both hands (temporary), normal temperature. On the 25th the foot ulcer was flatter, those on tongue and palate also diminishing. Improvement continued and on March 3 the general state of the patient was better, cyanosis of face and extremities gone, infiltration of hands diminished, finger ulcers rapidly healing; fingers could be flexed for the first time in more than a year (Plate 34, fig. 9).

Second blockade on March 6, 70 cc. in the muscles of left thigh. On the 7th the foot ulcer was cyanotic, fingers and hands edematous; the fingers were again fixed but that lasted for only a day. Though the patient acquired grippe (March 9) the foot ulcer continued healing, but that of the tongue extended.

Third blockade on March 18, 70 cc., right lumbar. Prompt development of edema of the fingers (two hours), but patient felt well; temperature normal. On the 19th the hands were edematous, cyanotic; fingers fixed, but not one day later. Foot ulcer healing rapidly, skin less infiltrated, softer and more elastic; no cyanosis. By April 7 the foot ulcer had healed (Plate 34, fig. 9), as had that of the palate; tongue ulcer diminishing.

The fingers kept the acquired mobility, the skin of the face and extremities was more elastic and more normal in color, the cyanosis having nearly disappeared. In some places the skin sensitivity was restored. General condition much improved.

Summarizing the results in this group, it may be said that the form of interference involved in novocaine blockade often influenced the course of local manifestations of leprosy, in spite of their "specific" character. Patches diminished, nodules became level, infiltrations resolved and ulcers healed, changes appearing in only a few days. We had cases in which a leprosy keratitis, accompanied by marked conjunctivitis and acute pain, healed in three weeks.

General reactions occurred immediately after the blockade in some cases, these consisting of fever, chill and rheumatic pains. Usually all this lasted for no more than a day and, as a rule, disappeared leaving no trace.

We think that the changes in the ulcers provoked by this

treatment may be, to a certain degree, typical of the cycle of the process that takes place in other specific conditions. Ulcers are of two kinds, those that appear after breaking down of nodules and those formed as a result of trauma, but both kinds have the same cycle of changes. Subjective sensations after the blockade are generally identical. Shortly after it pain is felt in the area of the ulcer, similar to an irritation by an electric current; as a rule it disappears the next day. There is an exacerbation, the flabby, indolent lesion changing into a fresh wound. There is an abundant secretion of pus, the dirty grayish color disappears, granulations become "lively" and pink, and if the ulcer is surrounded by sound tissue it very soon begins to heal. Gradually the process again takes a slow, chronic course, but as a rule a second blockade leads again to exacerbation. Generally in two months many ulcers which had existed for years have healed.

Comparing these results with those obtained in the treatment of incurable ulcers of the lower extremities by the same method, we found them identical. Both specific leprous ulcers and simple chronic ones healed, passing through the same changes. The only difference was in the time of healing. Leprous ulcers healed in a few months, while simple ones healed more rapidly. At the Institute of Surgical Neuropathology, I observed the course of trophic ulcers after neurotomy of spinal nerves (Molotkov). After this intervention, as after the blockade, there was on the next day a singular feeling of pain in the ulcer. This soon passed, the secretion became purulent, granulations acquired a fresh aspect, and the ulcer, after exacerbation, began to heal. This leads to the conclusion that the blockade does not act directly on the tissue elements but through the nervous system, the changes of which only gradually modify the course of local affections.

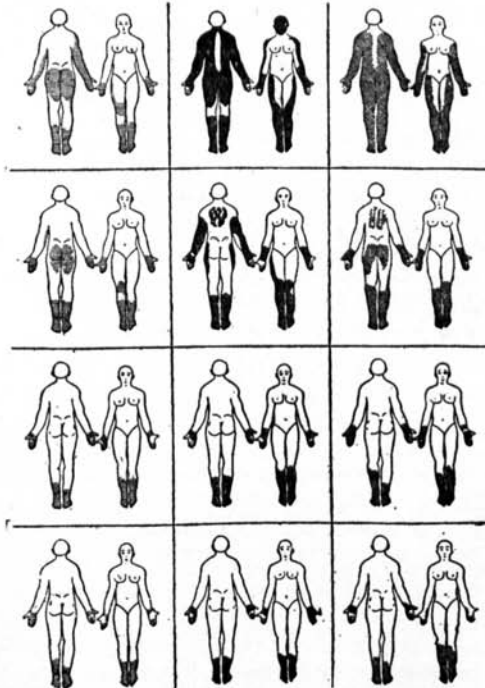
The second case described above is of particular interest, for it proves that nerve influences create an organizing stimulus for the development of the leprous process at the periphery. This patient had contracture of the fingers (*main en griffe*) of both hands, with leprous infiltrations of the skin and slight edema. Fifteen days after the blockade the fingers were flexible and the infiltration subsided. After the second blockade the fingers were again fixed in a flexed position, but on the next day that passed and they were more flexible than after the curative effect. Both forms of reaction were an answer to the same interference, and characterized different phases of the process.



## GROUP II

In the cases that have been described we noticed, besides changes in the local lesions, other changes in the functions of the nervous system: restoration of sensitivity and increase of motor capacity and muscular strength. This observation led to a special line of investigation. In a second group of about 20 patients attention was paid chiefly to the sensory and motor functions. To exemplify the findings the following cases are given in summary:

CASE 3. K.A., male, aged 44, mixed leprosy. First symptoms appeared after a cold in 1915 with edema of legs and face, then pains in the feet, followed by patches on face and arms. Not diagnosed until 1924, when he entered the settlement with nodules on the face, arms and legs. Patient lean and pale, with flat nodules on face, forearms and feet, brown patches on trunk. Skin of forearms and feet infiltrated. Scars on hard palate, uvula destroyed. Suppurative scabs in the nose, with strong odor.



TEXT-FIG. 3. Diagrams showing changes in sensory disturbances of a case (Case 3) under treatment by novocaine blockade. The four rows show the findings at intervals within the period of one month. The three diagrams in each row show, left to right, the findings as regard tactile, pain and temperature sensitivity, respectively.

Vision of right eye nil (keratitis); that of left decreased, reaction to light weak, corneal and conjunctival reflexes normal. N. facialis not affected.

Hearing normal. Movements regular except lameness, a consequence of tuberculous coxitis in childhood. Tendon reflexes of extremities equal; sole reflexes absent. Abdominal reflexes weak but equal. Sensitivity (Text-fig. 3, top row): normal on chest and abdomen; tactile and temperature senses remain on face, that of pain lacking; proprioceptive sensitivity remains on hands, lacking on legs. Stereognosis of fingers of both hands reduced. Muscular strength reduced; dynamometry of right hand 26-20-26 kgm., left hand 12-10-12 kgm.

On March 1, 1934, injection of 100 cc. of the standard novocaine solution, left lumbar. On the 5th, changes in the anesthesia as shown in Text-fig. 3, second row. Dynamometry: right hand 28-26-28 kgm., left hand 16-12-16 kgm.

Another injection on March 12, 70 cc., right lumbar. In the evening pain was felt in the entire body. On the 15th, changes in sensitivity as shown in Text-fig. 3, third row. Dynamometry: right hand 30-28-30 kgm., left hand 24-24-26 kgm. On April 1 vision of left eye unchanged, pupil reaction decreased. All other reflexes as before except abdominal, which were normal. Changes in skin sensitivity as shown in Text-fig. 3, bottom row; proprioceptive sensitivity retained on hands, lacking on legs. Stereognosis of fingers on both hands entirely restored. Patient easily distinguishes pen, needle and other small objects, which he could not do before. Dynamometry: right hand 36-38-36 kgm., left hand 28-28-28 kgm.

CASE 4. D.M., male, aged 66, mixed leprosy. First symptoms—red patches on the abdomen and arms with strong pains in the legs—appeared after a cold in 1913. Transferred to the settlement in 1933. Patient of solid build, well nourished. Skin of face infiltrated, supraciliary arches thickened, eyebrows sparse; conjunctivitis of both eyes. Scabs on nasal mucosa. Large, red, raised patches on abdomen, chest and back; color unchanged on pressure. Skin of forearms, hands and feet infiltrated, folded with difficulty; hands and fingers thickened and cyanotic.

Vision of both eyes decreased, pupil reaction weak, corneal and conjunctival reflexes normal. N. facialis not affected. Movements and gait regular but very slow. Tendon reflexes weak, equal. Sole reflexes absent. Abdominal reflexes weak. Extensive disturbance of skin sensitivity as shown in Text-fig. 4, top row. Proprioceptive sensitivity of arms and legs lacking. Stereognosis of fingers of both hands; such objects as an axe, mittens on his hands, etc., are not felt. Muscular strength reduced; dynamometry of right hand 32-26-28 kgm., left hand 8-8-6 kgm.

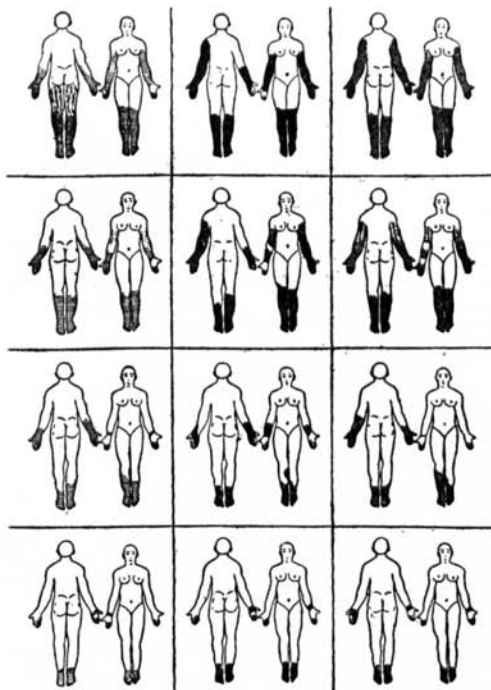
On March 19, 1934, injection of 100 cc., left lumbar. In the evening a feeling of pain all over the skin, with chill. On the 23rd, tissues of extremities and about the patches were much less infiltrated, patches lighter and yellowish. Conjunctivitis disappeared. Pupil reaction to light normal. Tendon reflexes also normal, abdominal reflexes equal, sole reflexes absent. The areas of skin sensitivity had extended (Text-fig. 4, second row). Stereognosis on both arms had passed, patient distinguishing small objects, even needles. Dynamometry: right hand 34-34-36 kgm., left hand 32-32-28 kgm.

Another injection on April 1, 100 cc., right lumbar. On the 4th, patches on body yellowish; sensitivity had appeared in some. Changes in skin sensitivity as shown in Text-fig. 4, third row. Dynamometry: right hand 36-



36-36 kgm., left hand 32-28-32 kgm. Vision as before. On the 9th, corneal and conjunctival reflexes were regular. Sole reflex had appeared on both sides. Changes in skin sensitivity as shown in Text-fig. 4, bottom row. Proprioceptive sensitivity on arms restored, but lacking on legs. Muscular strength average.

The patient was feeling well and had become much stronger. The patches were much lighter, though they had not disappeared.



TEXT-FIG. 4. Showing similarly the changes in sensory disturbances in another, similarly treated case (Case 4), at intervals within a period of three weeks.

Summarizing the observations on this group, it is to be said that changes in the general course of leprosy manifestations were obtained, particularly as regards the sensory and motor disorders. All kinds of skin sensitivity, in areas where they had been lacking for some years, were restored soon after the novocaine blockade had been administered.

Topographically, restoration of sensitivity took place first on the trunk as a rule, and then on the face and extremities—in proximal parts sooner than in distal ones. It occurred sooner on the upper extremities than on the lower ones, but the ulnar surface of the hand

was the last to be restored. There was no regularity with regard to the order of restoration of the different kinds of sensitivity.

Skin and tendon reflexes, if lacking, were restored, and if they were irregular on the two sides they became equal. In many cases protopathic sensitivity was restored. As a rule stereognosis of fingers was restored. Muscular strength began to increase the first day after the blockade, and then gradually increased for two to three months.

How are these results to be explained? It is possible that we have here the following phenomena. It is known that in leprosy there is a complete degeneration of sensory and motor nerve fibers as well as the first phases of a peripheral neuritis. In cutaneous (nodular) leprosy there are granulomas in the peripheral nerves, and in the neural form there is interstitial neuritis. Novocaine blockade often affects strongly the course of inflammatory processes, and it would seem that it does so with respect to the inflammatory processes in the nervous system itself.

The clinical picture of the restoration of sensation is reminiscent of the course of other neurotrophic processes. All of the patients, soon after the blockade, had pains—paresthesias—in the anesthetic areas, which means that first there was an exacerbation of the process, followed by the therapeutic effect. Also, some of them had, together with the decrease of the anesthetic areas, a temporary increase of the sensory disorders in limited areas after the blockade. Thus activation of processes in the inflammatory foci may be manifested by their temporary extension.

Undoubtedly, restoration of sensitivity in our cases took place only in nerves in which there were inflammatory phenomena but not degeneration. It follows that the restoration of skin and tendon reflexes happened on account of diminution and disappearance of inflammatory foci in sensory and motor nerves. Noteworthy is the increase of muscular strength after the blockade, sometimes occurring after only one day.

Positive results were obtained in all of the cases in this group. However, in further work we had five cases in which the treatment had no effect on either the sensory or motor disorders.

#### GROUP III

The fact that the novocaine blockade effects various changes in the course of the leprosy process led us to apply it in lepra reaction. Thirty patients were in this group. The treatment acted to abort the condition.

CASE 5. B, female, aged 37, secondary neural. Early in 1908 insensitive patches appeared on the extremities, later on face and body. Finally there developed generalized nodules which disintegrated and healed. Such eruptions lasted for two or three months and appeared two or three times a year for three years. Treated with hydnocarpus oil and thymol, there had been no exacerbation for twelve years. Patient of regular build, well nourished. Small, atrophic, depigmented scars generalized, most numerous on extremities. Partial depilation of eyebrows. Nose thickened and depressed, nasal mucosa atrophied. Lymphatic glands of thigh enlarged. Tactile sensitivity present in the scars, pain and temperature sensation decreased. Vision and hearing normal.

Patient fell ill on February 17, 1934, with chill and pain in the left foot, which became edematous. Pain developed in the arm and in the area of the thigh glands, and a feeling of burning in the leg. Temperature 39.2°C. Entered hospital on the 19th. Left foot edematous, very red and painful to touch. Temperature 38.3°C; complaint of headache and loss of appetite. Injection of 120 cc. of the novocaine solution, left lumbar. Evening temperature 37.5°C. On the 20th, temperature slightly less, no headache, much less burning and pain in leg, none in the glands; erythema of foot diminished, edema persisting. There was a small group of bright red, millet-sized nodules, painless to touch, on right forearm. Evening temperature 37.0°C. On the 21st, temperature normal (remaining so thereafter) and patient feeling better. Erythema of foot almost gone, pain on touch less and edema decreased. New nodules on forearm more flat, diffuse; similar ones, symmetrically disposed, seen on left forearm; in the evening they had fused in pink patches. In two more days the erythematous lesions had almost disappeared whereas in former exacerbations, she stated, such lesions were more painful and new nodules either did not resolve or took one to two months to do so. She left the hospital on the 25th.

This patient was given the blockade because of "erysipelas" (lepra reaction) affecting the leg. On the following day new nodules appeared on one and then the other forearm, but these disappeared in two days, much more quickly than usual.

CASE 6. A, female, aged 26, mixed leprosy. Fell ill at the age of 17, after typhoid fever; she noticed on the right foot two small, thick, red nodules which later disappeared. No further symptom for six years, when on right forearm there appeared livid patches which also soon disappeared; after that had pains in both feet. Entered a leprosarium in 1931 and under treatment (moogrol) nodules became reduced. Patient well developed and nourished. Thick subcutaneous nodules on face, forearms and feet, and festooned patches on trunk; skin cyanotic, eyebrows sparse, lymphatic glands enlarged—in general, marked leprotic changes. Vision normal. Skin sensitivity decreased. *M. leprae* in nasal mucosa. On November 20, 1933, abdominal Caesarean section was performed, after which the nodules diminished in size and number.

On February 9, 1934, she experienced pain in left hand, extending to shoulder; chill, headache, general discomfort; temperature 38.6°C. Entered hospital on the 10th. Temperature 37.6°C. Skin of left hand and forearm inflamed, copper-red, painful and edematous. New small (pea to millet size)

nodules palpable among large oval ones, chiefly on extensor surface; skin over the small nodules intensely red, over the large ones cyanotic. Edema of arms, which are livid and ulcerated over the articulations on the extensor surfaces. Skin of right forearm, face, etc., without reaction phenomena. Injection, 150 cc., left lumbar. Marked headache followed, but pain in left hand ceased at once. Temperature, 36.7°C. On the 11th the patient looked well, pain in left hand present but much diminished; able to lift arm, flex elbow and close fist. Edema decreased, erythema more regular and paler. No fever. On the 12th, movements painless, edema remaining only in fingers; small nodules softer and quite flat, large ones thick but painless. Left hospital next day. Re-examined on the 22nd: general state good, old nodules flattening, finger sensitivity improved.

Anybody familiar with the treatment of lepra reaction must agree that the therapeutic effect after the blockade was quite satisfactory. The exacerbation was stopped in a few hours, the general state of the patient was improved, pains ceased, temperature decreased. In two to three days the local phenomena (erythema, edema, new nodules, eruption) disappeared, and often old lepromata were beginning to diminish. Obviously the various symptoms which together form the clinical picture of lepra reaction are not directly connected with each other. We observed that the disappearance of one or two of these symptoms did not involve changes in the state of the others. As we were acting upon the nervous system, the latter created conditions which contributed to the development and liquidation of the reaction.

#### DISCUSSION

Most leprosy investigators consider that this disease develops first peripherally, the microbe then gradually penetrating into the organism, as in the ascending neuritis. The pathologic symptom complex is considered as due to local tissue reaction to the specific irritant, the nervous system suffering only passively. Even the symmetrical disposition of patches and anesthasias is explained as a singularity of the hematogenous distribution of the microbe. The question of the central nervous system having an active part in the process has not even been approached. Our observations of the improvement which follows interference with a separate area of the complicated nervous system in which the pathologic process does not occur, have led us to conclude that the nervous system has the chief and active part in the organization of all the painful manifestations of leprosy.

Leprosy bacilli are often found in the nasal mucosa of leper settlement attendants, and most of them—as well as patients—give a positive reaction to leprolin (Stein, Shecheperin), yet only a very

small proportion of them are affected with leprosy. The microbe can, according to reports in the literature, remain in the body until death without provoking the disease. Doubtless because of its low toxicity, it is a weak irritant, as has been shown by studies of the pathological changes which it causes, and it requires great susceptibility of the individual to produce infection.

One must think that here the leading part is, first, the hereditary structure of the nervous system, and second, its subsequent changes acquired during life. The long incubation period of leprosy is explained not by the period of time necessary for the reproduction of microbes, but by the slow development of suitable forms of the dystrophic process. Some supplementary disturbance, such for example as a cold, can hasten the appearance of external symptoms, having created a condition favorable for the multiplication of the bacillus—perhaps, as Kedrowsky has held, for its conversion from an inactive to an active form. Contradictory results of human inoculation (as the negative ones by Danielsen and positive ones by Daubler) indicate that the leading part belongs not to the microbe but to the substrate.

In our work, by an interference which does not directly destroy the microbe but produces changes in the nervous system, we have obtained changes not only in the general course of the process but also in its specific symptoms. Temporary exclusion of a part of the nervous system by anesthesia, with subsequent restoration of the disturbed relations, creates for a period new conditions which make more difficult the manifestation of the pathological process at the periphery. We consider that the nervous dystrophy determines not only the appearance of the painful process, but also the character of its clinical course.

The order of the changes in different organs and parts of the body is to be explained more easily by the active development of the dystrophic process in the nervous system than by the nature of the microbe itself. Speransky and his collaborators have discovered a regular course of the dystrophic processes in the nervous system after quite different traumas of it. Clinical observations of A. V. Vishnevsky on novocaine blockade in cases of ordinary inflammation have proved the organizing part of the nervous system in the inflammatory reaction. We explain the results obtained in leprosy by the action of the novocaine blockade through the nervous system on the common inflammatory component which accompanies the specific leprosy process. The mechanism of action of novocaine blockade will be treated in another article, but it may

be said that we consider it as a method of weak irritation of the nervous system, changing on the whole its trophic status.

With regard to the effect of the blockade in leprosy, it is to be noticed that its immediate therapeutic effect is more rapid than that of any other well known method of treatment. All our patients had been subjected to different kinds of "specific" treatments, but with less results than after the blockade.

The period of our observations is short. That is the weak point of our investigation, but it also makes it more valuable in that we could establish a direct connection between our interference and the immediate effect, and plead for our conception of the pathogenesis of leprosy. The future will show whether novocaine blockade will take a place in the treatment of this disease. If it proves to be an auxiliary method that can prepare the ground for some other form of interference, we shall be quite satisfied.

#### REFERENCES

- (1) VISHNEVSKY, A. A., JR. The technique of novocaine blockade of the lumbar section of the sympathetic nervous system. *Arch. of Biol. Sci.* (1934).
- (2) VISHNEVSKY, A. A. AND GOLYSHEWA. Zur Frage der Prädisposition. *Zeitschr. Ges. Exp. Med.*, **89**. (1933) 105-12.
- (3) VISHNEVSKY, A. V. Der Novokainblock als eine Methode der Einwirkung auf die Gewebetrophik. *Zentrbl. Chir.* **62** (1935) Nr. 13.

#### DESCRIPTION OF PLATE

##### PLATE 34

FIG. 1. Case 1. Leprous ulcers on the anterior surfaces of the legs, before treatment.

FIG. 2. The same, a month after the beginning of treatment by the novocaine blockade; stage of exacerbation.

FIG. 3. The same, showing complete healing of the ulcers three months after the beginning of treatment.

FIGS. 4 and 5. Case 2. Contractures of fingers, before treatment. Fig. 4, maximum flexion; Fig. 5, maximum extension.

FIGS. 6 and 7. Same case, fourteen days after treatment by lumbar novocaine blockade. Fig. 6, maximum flexion; Fig. 7, maximum extension.

FIG. 8. Same case. Leprous ulcer of the ankle, of four years duration, before treatment.

FIG. 9. Same case. Ulcer healed 47 days after the beginning of treatment by novocaine blockade.



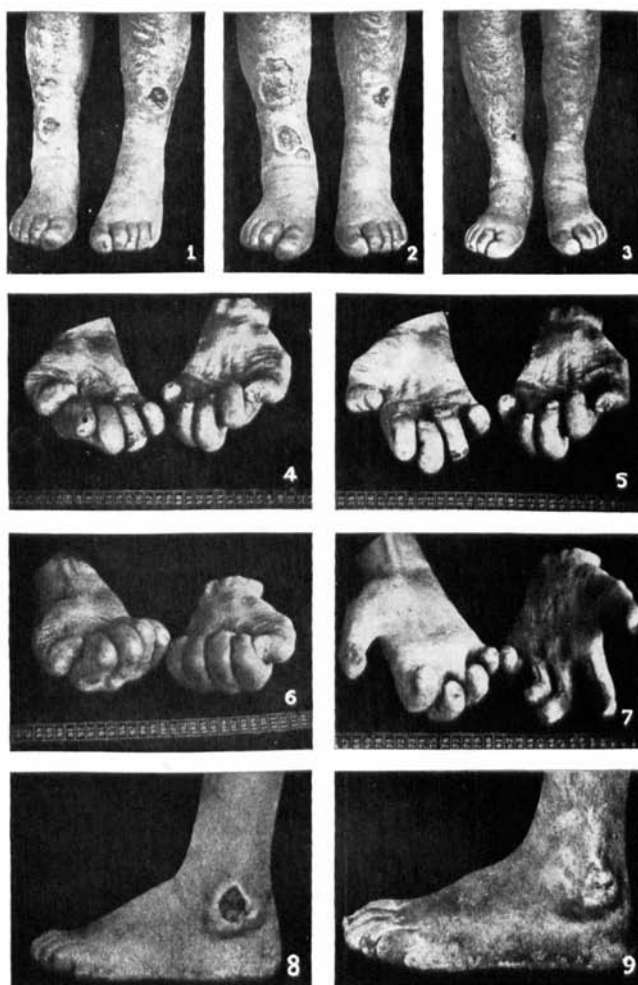


PLATE 34